



N·E·V·S

NEW ENGLAND VETERINARY SPECIALISTS

Echocardiogram Report

Date: 02/26/2016

Name: collins, ai no hoshi

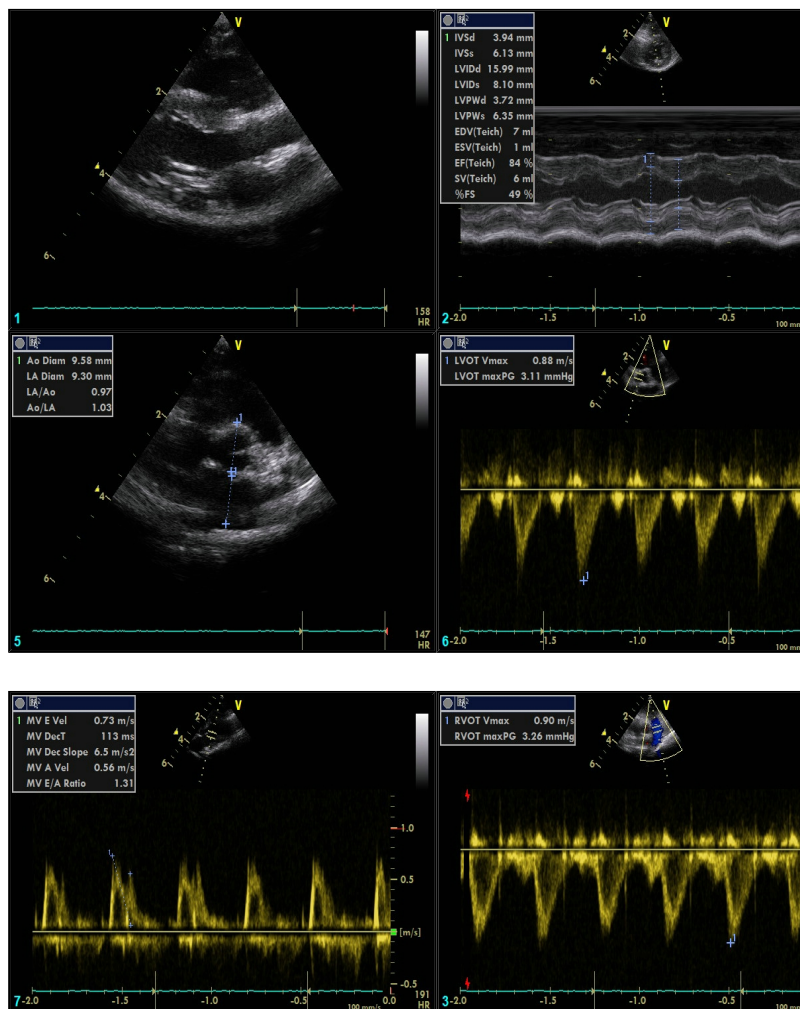
Breed:

Age:

Sex:

Ref Vet:

Weight:



Cardiac Measurements:

<u>2-D</u>		<u>M-Mode</u>		<u>Doppler</u>	
Ao Diam	9.58 mm	IVSd	3.94 mm	MV E Vel	0.73 m/s
LA Diam	9.30 mm	LVIDd	15.99 mm	MV DecT	113 ms
LA/Ao	0.97	LVPWd	3.72 mm	MV Dec Slope	6.5 m/s ²
Ao/LA	1.03	IVSs	6.13 mm	MV A Vel	0.56 m/s
		LVIDs	8.10 mm	MV E/A Ratio	1.31
		LVPWs	6.35 mm	LVOT Vmax	0.88 m/s
		EDV(Teich)	7 ml	LVOT maxPG	3.11 mmHg
		ESV(Teich)	1 ml	RVOT Vmax	0.90 m/s
		EF(Teich)	84 %	RVOT maxPG	3.26 mmHg
		%FS	49 %		
		SV(Teich)	6 ml		

Physical exam:

HR: 160, regular rhythm, no murmur appreciated today, moderate and synchronous pulses, clear and eupnic, no jugular pulsations or distention is noted. color is pink and refill is less than 2s.

Thoracic radiographs:

- There are no contemporary thoracic radiographs for review.

ECG:

- A sinus rhythm was present throughout the echo. No significant atrial or ventricular ectopy is appreciated.

2D and M-Mode:

- The left ventricular internal dimensions are normal.**
- There is no hypertrophy of the interventricular septum, the left ventricular posterior wall or papillary muscles.**
- The mitral valve leaflets are normal.**
- The tricuspid valve leaflets are normal.**
- The indices of left ventricular contractility are normal.**
- The left atrium is normal.**
- The right ventricular dimensions are normal.**

Color and Spectral Doppler:

- The aortic spectral Doppler velocity and profile are normal.**
- The pulmonic spectral Doppler velocity and profile are normal.**
- The transmitral E and A waves are normal.**

Diagnosis:

Normal echocardiographic examination

Treatment:

- There are no cardiac medications indicated at this time.**
- Follow**

MARK E STAMOULIS DVM ACVIM (CARDIOLOGY)